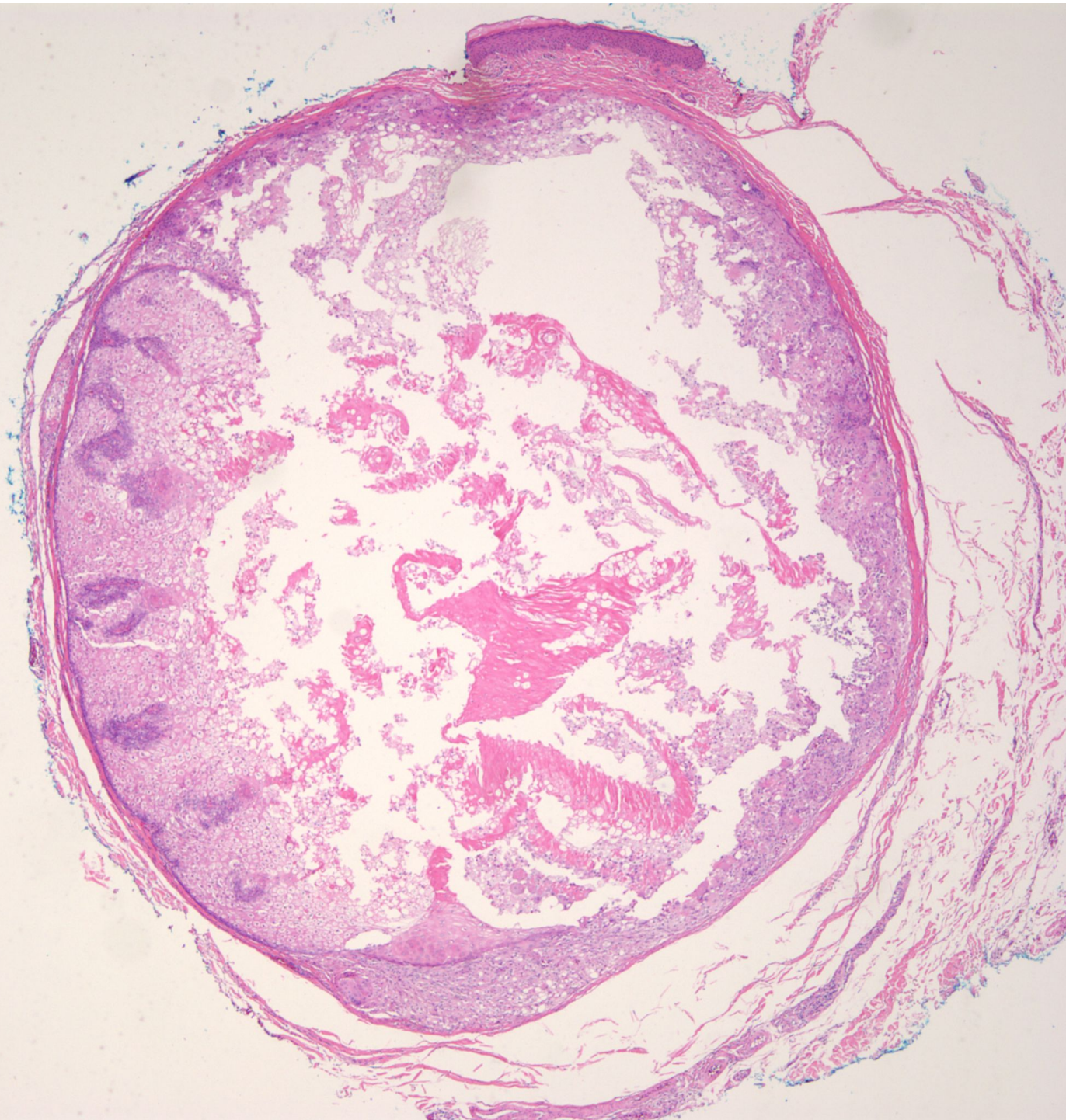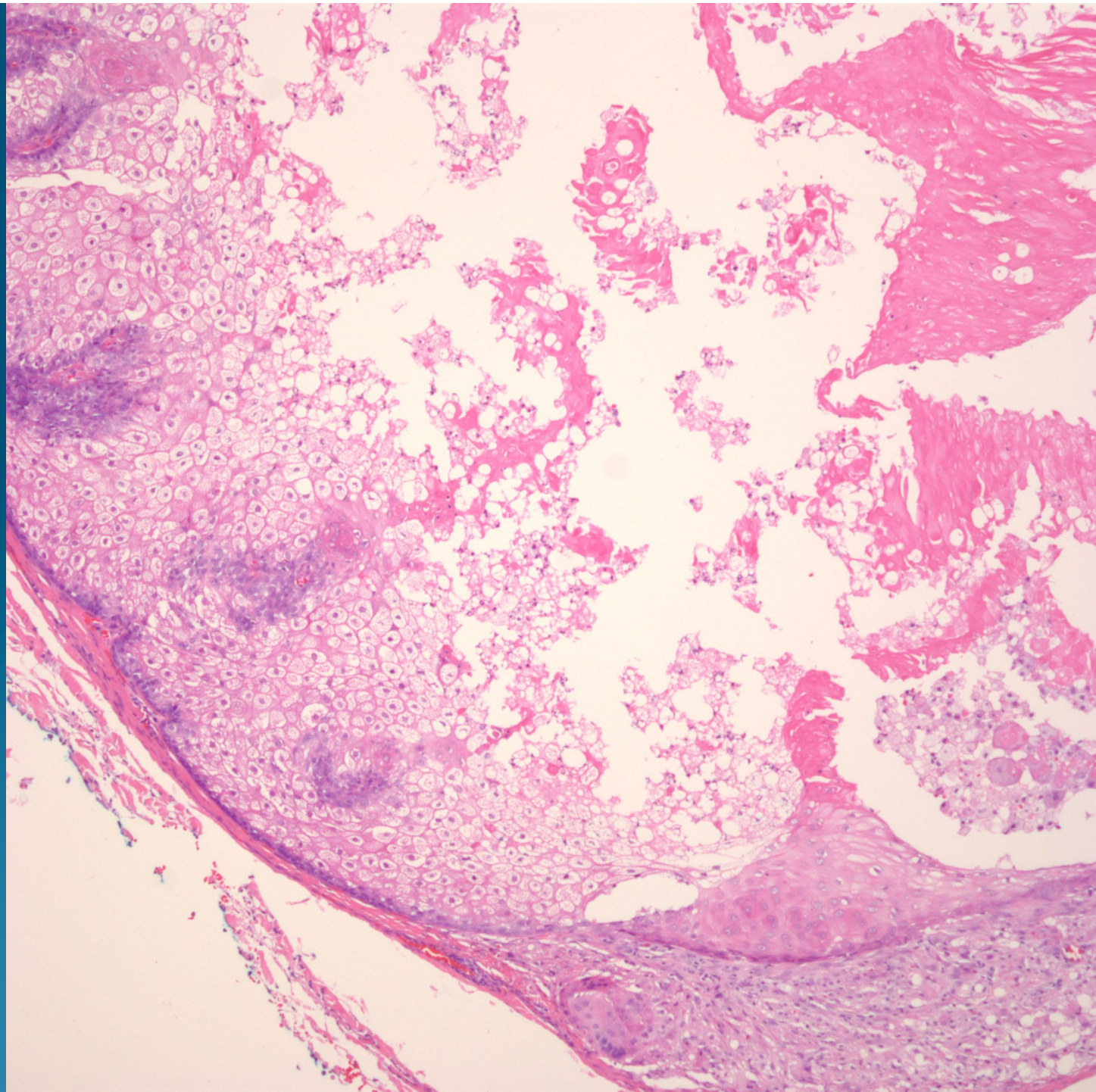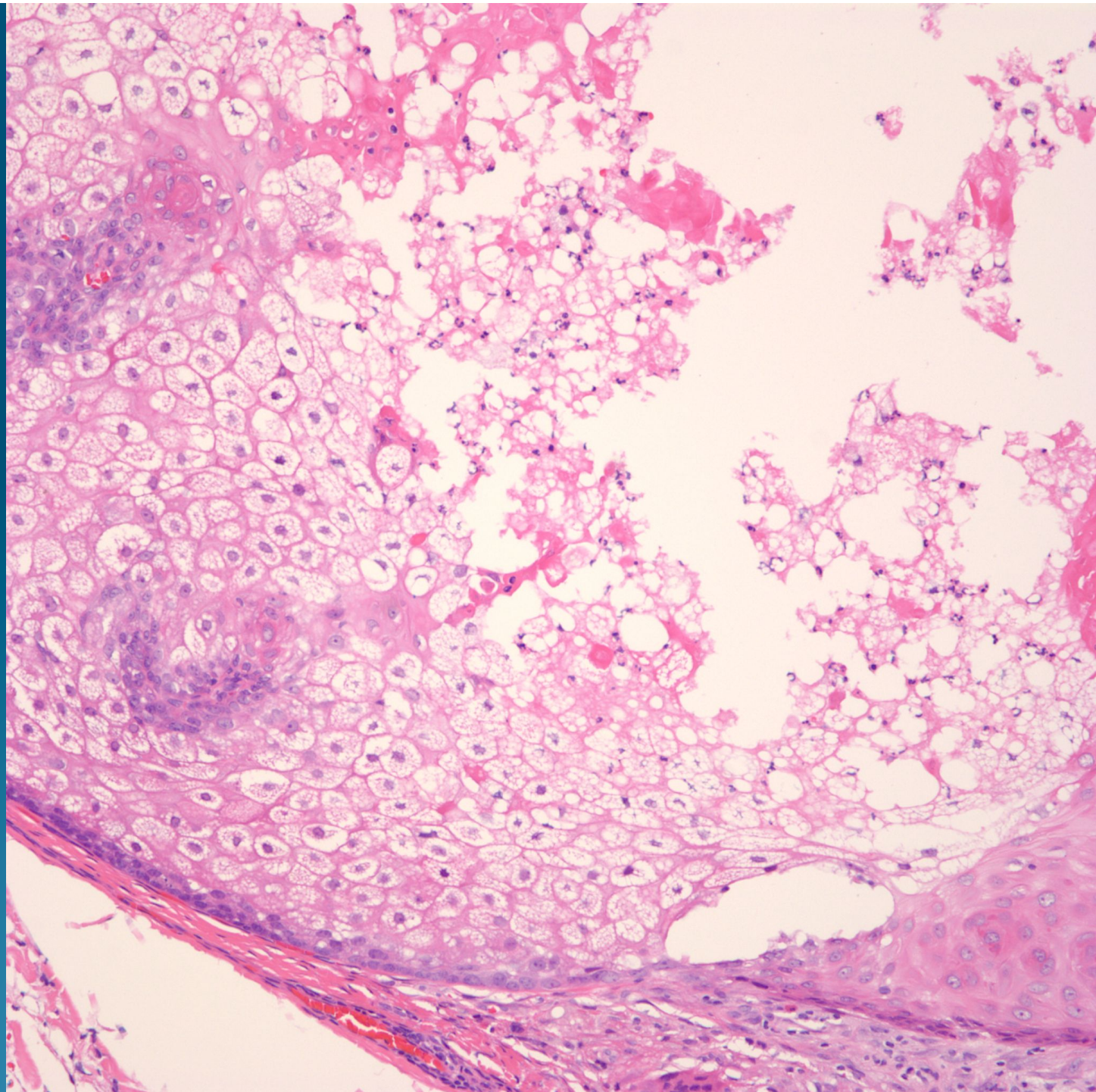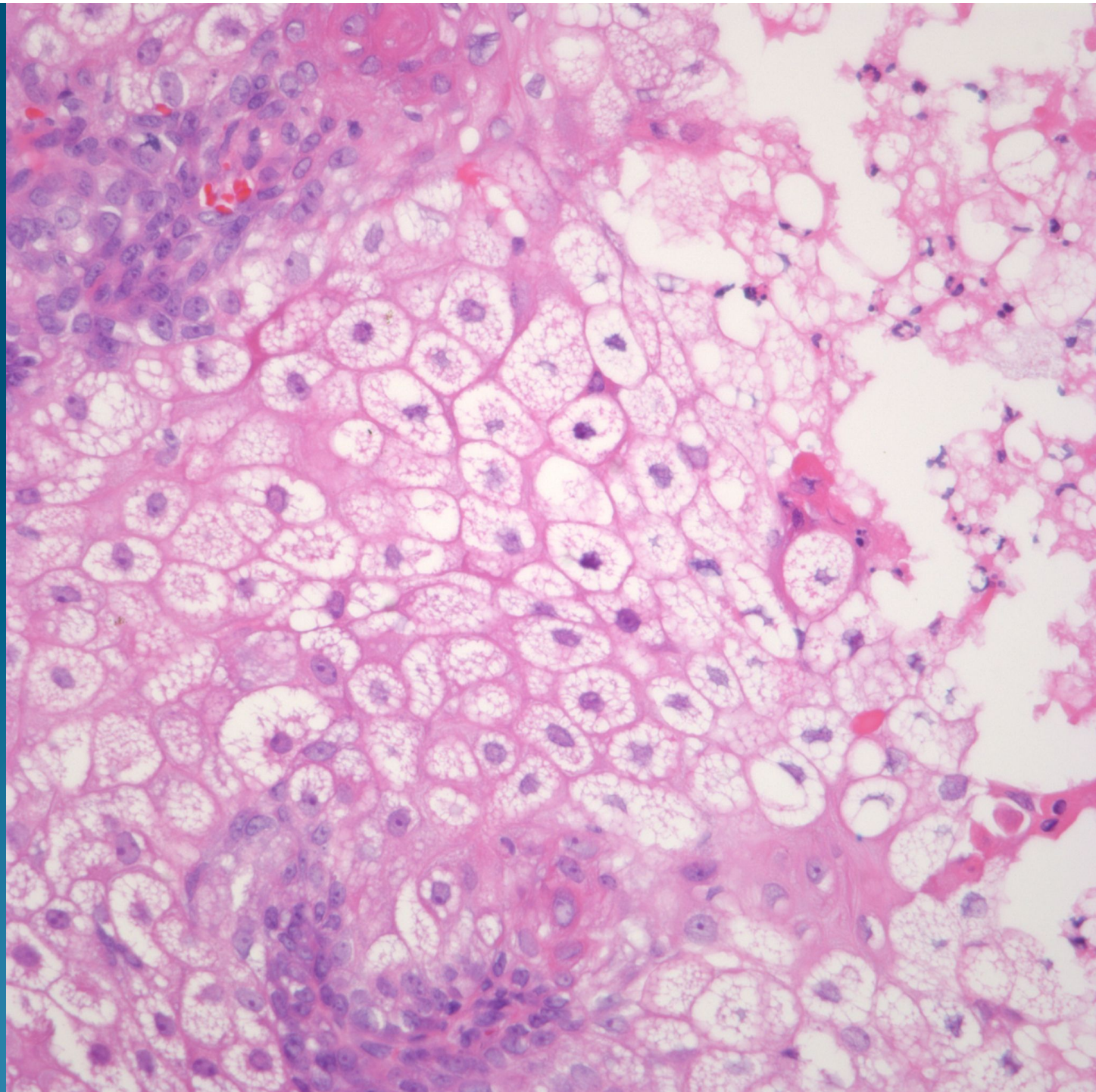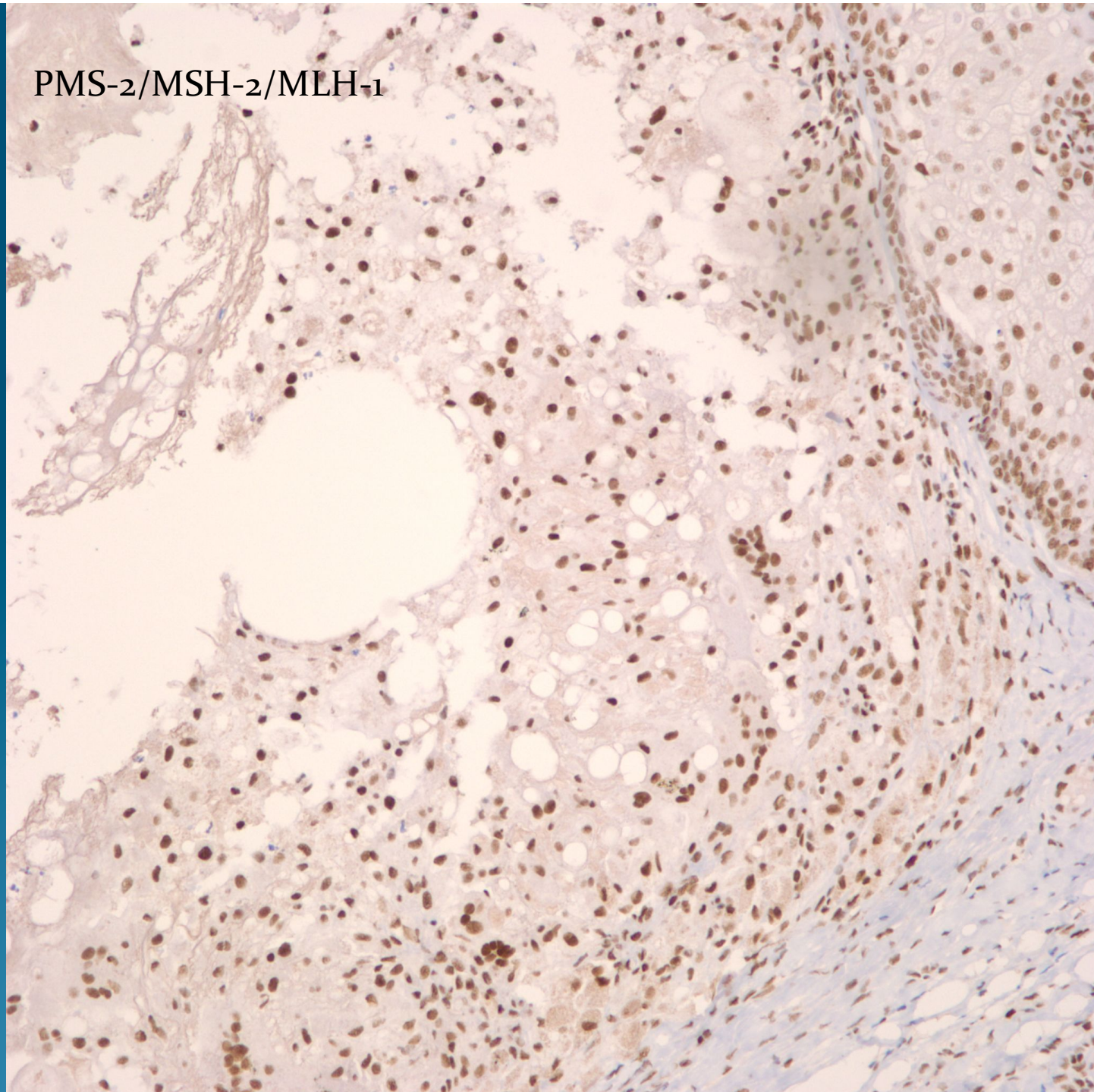
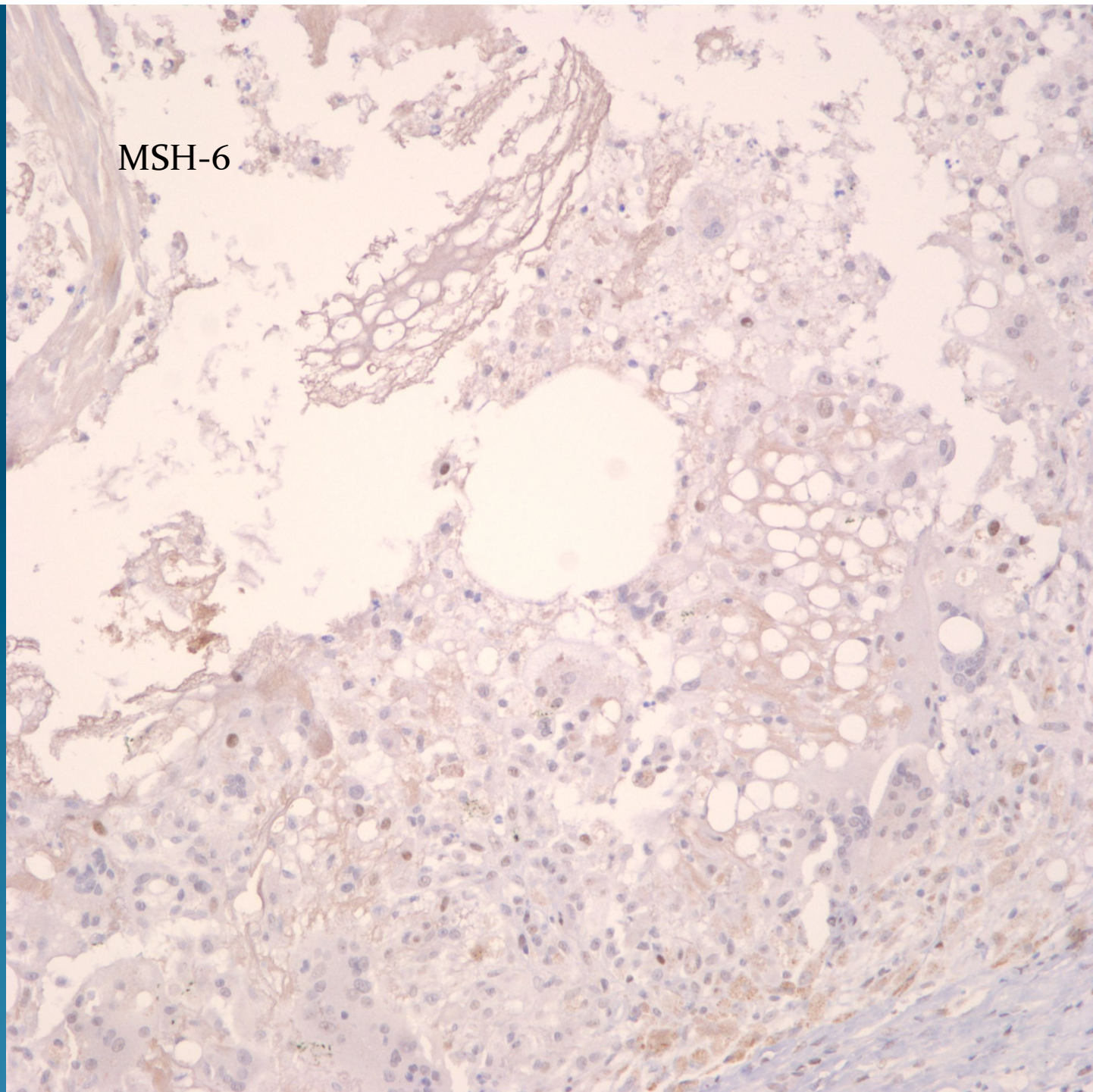


PMS-2/MSH-2/MLH-1



MSH-6



Cystic Sebaceous Adenoma Suggestive of Muir-Torre Syndrome

Notes

- All sebaceous neoplasms are potential markers for Muir-Torre syndrome
- Sebaceous tumors with cystic change and verruciform features are more frequently associated
- May confirm with DNA Mismatch repair genes (look for loss of staining)
 - MSH-6
 - PMS-2
 - MLH-1
 - MSH-2

Circum-
Scribed
Dermal
Tumor
Of mature
sebocytes

Cystic
change

